

# Orthodontic aspects of the use of oral implants in adolescents: a 10-year follow-up study

Birgit Thilander\*, Jan Ödman\* and Ulf Lekholm\*\*

\*Department of Orthodontics and \*\*The Brånemark Clinic, University of Göteborg, Sweden

**SUMMARY** The aim of the present study was to evaluate the long-term effect of implants installed in different dental areas in adolescents. The sample consisted of 18 subjects with missing teeth (congenital absence or trauma). The patients were of different chronological ages (between 13 and 17 years) and of different skeletal maturation. In all subjects, the existing permanent teeth were fully erupted. In 15 patients, 29 single implants (using the Brånemark technique) were installed to replace premolars, canines, and upper incisors. In three patients with extensive aplasia, 18 implants were placed in various regions. The patients were followed during a 10-year period, the first four years annually and then every second year. Photographs, study casts, peri-apical radiographs, lateral cephalograms, and body height measurements were recorded at each control.

The results show that dental implants are a good treatment option for replacing missing teeth in adolescents, provided that the subject's dental and skeletal development is complete. However, different problems are related to the premolar and the incisor regions, which have to be considered in the total treatment planning.

Disadvantages may be related to the upper incisor region, especially for lateral incisors, due to slight continuous eruption of adjacent teeth and craniofacial changes post-adolescence. Periodontal problems may arise, with marginal bone loss around the adjacent teeth and bone loss buccally to the implants. The shorter the distance between the implant and the adjacent teeth, the larger the reduction of marginal bone level. Before placement of the implant sufficient space must be gained in the implant area, and the adjacent teeth uprighted and paralleled, even in the apical area, using non-intrusive movements. In the premolar area, excess space is needed, not only in the mesio-distal, but above all in the bucco-lingual direction. Thus, an infraoccluded lower deciduous molar should be extracted shortly before placement of the implant to avoid reduction of the bucco-lingual bone volume.

Oral rehabilitation with implant-supported prosthetic constructions seems to be a good alternative in adolescents with extensive aplasia, provided that craniofacial growth has ceased or is almost complete.

## Introduction

The number of long-term reports on endosseous implant treatment in children and adolescents with missing teeth is limited. Consequently, it has become increasingly clear that there is a need for more information as to whether dental implants in young dentitions should be used at all, and if so, how and when. It has to be realized

that this treatment protocol, creating an intimate contact between implant and bone, i.e. osseointegration, was designed and evaluated for the mature skeleton (Brånemark *et al.*, 1977). Today, the method is well established in the management of totally and partially edentulous jaws, and for single tooth replacement in adult patients (Esposito *et al.*, 1993; Henry *et al.*, 1996; Lekholm *et al.*, 1999). Observations in the growing pig have

indicated excellent biocompatibility of Brånemark implants even in young alveolar bone (Sennerby *et al.*, 1993).

From the experimental studies in the growing pig it has also been shown that osseo-integrated titanium implants do not behave like normally erupting teeth during dento-alveolar development and growth of the jaws, resulting in infraocclusion (Ödman *et al.*, 1991; Thilander *et al.*, 1992). The conclusion from these experimental investigations, confirmed in a clinical investigation, was that dental implants should not be inserted in young individuals, until the permanent dentition is fully erupted and skeletal growth is complete to avoid infraocclusion of the implant-supported crown (Thilander *et al.*, 1994). However, studies have demonstrated that significant changes in craniofacial dimensions occur in man even during adulthood (Sarnäs and Solow, 1980; Björk and Skieller, 1983; Behrents, 1985), including changes of the dento-alveolar height, indicating eruptive movement of the teeth (Forsberg *et al.*, 1991; Tallgren and Solow, 1991). A slight continuous eruption of teeth has also been observed even after established occlusion post-adolescence (Ainamo and Talari, 1976; Iseri and Solow, 1996; Thilander *et al.*, 1999).

Considering these late dimensional changes, the aim of the present study was to evaluate the long-term effect on occlusion and marginal conditions of osseo-integrated titanium implants, installed in adolescents to replace missing teeth in different dental areas.

## Subjects and methods

### Subjects

When this study was outlined (1988) with the aim of testing results in the growing pig, the long-term effect of implants installed in young individuals was unknown. For ethical reasons, the investigation had to be carried out on a limited number of patients. The sample thus consisted of 18 adolescents (11 boys and seven girls) with missing teeth (congenital absence or trauma). Orthodontic space closure, auto-transplantation, and prosthetic replacement with fixed bridges had been excluded as treatment

procedures, but the implant technique was found to be a realistic choice in these patients.

A total of 47 implants (31 in the upper and 16 in the lower arch) were inserted using the standard Brånemark technique (Adell *et al.*, 1985), followed by implant crown placement 5–7 months later (Zarb and Jansson, 1985). In 15 patients, 29 single implants were installed to replace premolars, canines, and upper incisors, and in three patients with extensive aplasia 18 implants were placed in various regions (Table 1).

In all subjects, the existing permanent teeth were fully erupted (third molars excluded). Individual variations in eruption ages in children are rather extensive and endogenic, which implies that differences in chronological age, skeletal stage, and amount of residual growth are factors that must be considered, in addition to the dental stage. Thus, the age range of the present patients was rather wide (between 13 years 2 months and 17 years 2 months), as well as the skeletal maturation (from peak height of the growth curve to completed growth according to body height and hand-wrist radiographs, i.e. from MP3-FG to R-J according to Hägg and Taranger, 1980). All 15 patients with single implants have been described in detail elsewhere, in a table presenting gender, implant sites, age, and skeletal maturation at the time of implant placement (Thilander *et al.*, 1994).

**Table 1** Area location of the 29 single implants (15 subjects) and the 18 implants in extensive hypodontia (three subjects).

Area	Single implants	Extensive hypodontia
Upper arch ( <i>n</i> = 31)		
premolar	2	4
canine	2	4
incisor	17	2
Lower arch ( <i>n</i> = 16)		
premolar	7	
canine	1	1
incisor		7
Total ( <i>n</i> = 47)	29	18

### Registrations

The patients were followed during a 10-year period, the first four years annually and then every second year. Clinical examination, photographs, study casts, peri-apical radiographs, lateral cephalograms, and body height measurements were recorded at each control. The registrations and assessments have been described in more detail elsewhere (Thilander *et al.*, 1994). Of specific interest in the present study were long-term changes in the occlusion and marginal bone support at implants and adjacent teeth.

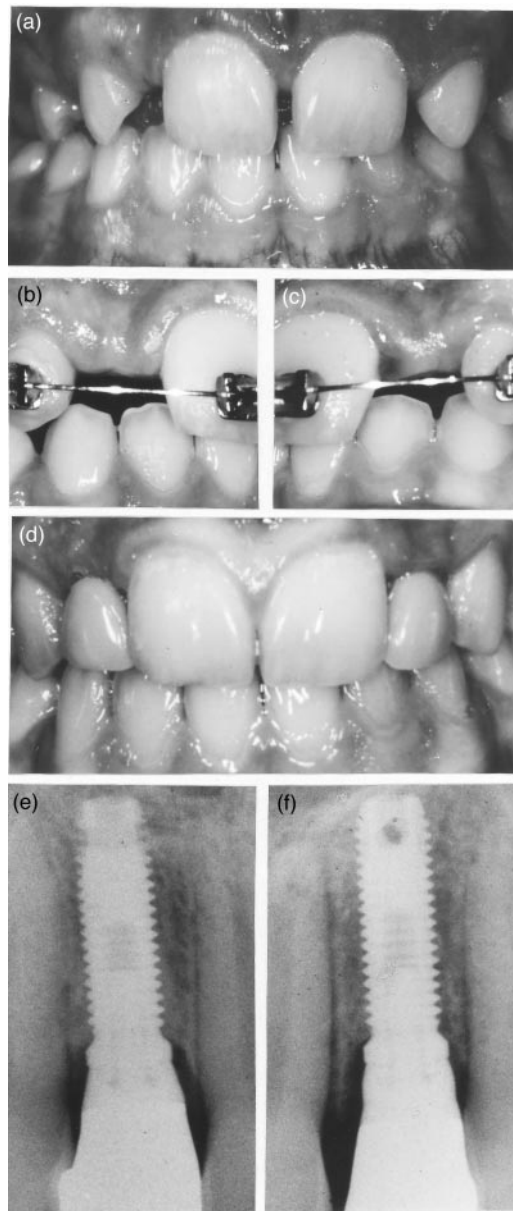
### Results

#### Overall findings

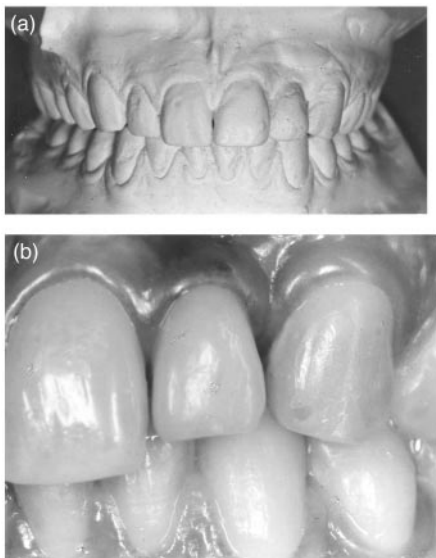
There were no implant losses during the observation period. A good to acceptable aesthetic appearance of the treatment outcome was found in most patients, depending on the area of implant placement, as described in detail below. The function, judged by the patient's chewing ability, was good in all subjects.

#### Single implants in upper incisor regions

In 10 of the adolescents, 17 implants had been placed (13 in the lateral and four in the central incisor regions). At the end of the observation period a good or acceptable aesthetic appearance was noted for 10 of the implant-supported crowns, exemplified by Figure 1. For the other seven, however, a change in the vertical position of the implant-supported crown was found, resulting in infraocclusion (Figures 2, 3 and 4). An infraocclusion, from 0.6 to 1.6 mm, was already present at the 3-year control and verified from superimpositioning of the cephalograms, which demonstrated craniofacial growth changes related to an increase in body height (3–18 cm), as described elsewhere (Thilander *et al.*, 1994). From the 4-year observation, no further increase in body height, nor any craniofacial changes were found in any of the patients. However, an increase in infraocclusion with individual variations was observed. The mean incisal vertical change had gradually increased to 0.98 mm



**Figure 1** A 14-year-old boy with congenitally missing upper lateral incisors (a). After space gaining (b,c), implants were placed at the age of 16 years 4 months, skeletal stage R-IJ. The final control (at 26 years 11 months) showed a good long-term result (d), i.e. inter-incisal stability and no infraoccluded implant-supported crowns. Peri-apical radiographs with no marginal bone loss, either at the implants or at the adjacent teeth (e,f). The increase in body height during the 10-year observation period was 0.5 cm.

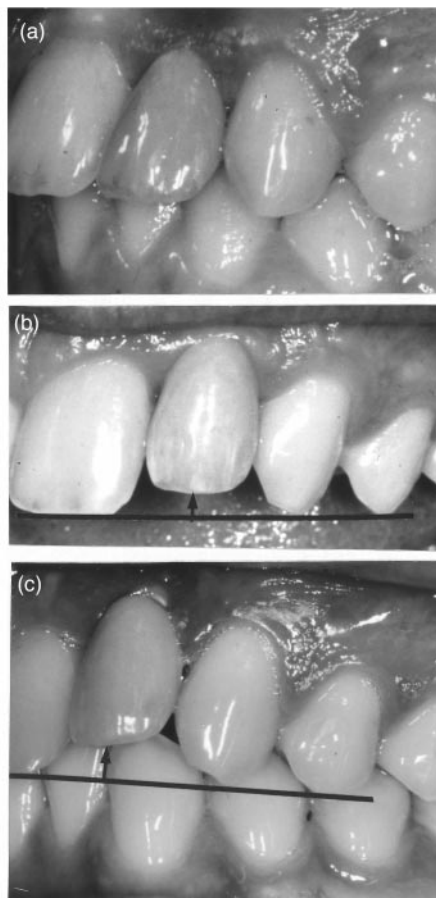


**Figure 2** Study casts of a girl (14 years 2 months old, skeletal stage MP3G) with the congenitally missing left upper lateral incisor replaced by an implant-supported crown (a). At the latest observation (25 years 1 month), an infraocclusion (0.8 mm) was registered at the implant-supported crown (b). The increase in body height during the whole observation period was 4.5 cm.

during the whole observation period, i.e. 0.1 mm per year (Table 2). There was not only a difference in the level aspects between the incisal edges (range 0.1–2.2 mm), but in a few cases an apical shift of the soft tissue margin of the implant-supported crown could also be seen (Figure 3).

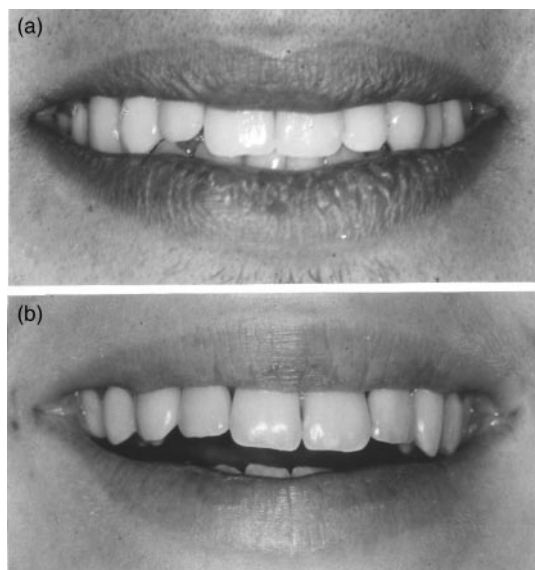
An infraoccluded position of an implant-supported crown of only minor degree may mean an unsatisfactory appearance in patients with a unilateral implant (Figure 4a). In subjects with bilateral infraoccluded implant-supported crowns, however, only minor or no aesthetic problems may occur, due to symmetry (Figure 4b).

Throughout the follow-up period, only minor loss of marginal bone support at implants was observed in all but three implants. Radiographic assessments (Figure 6) showed that most marginal bone loss occurred between abutment connection and crown placement (mean 0.5 mm,



**Figure 3** A boy (15 years 5 months old, skeletal stage MP3-FG) with a congenitally missing left upper lateral incisor replaced by an implant-supported crown (a). At the 3-year control, an infraocclusion of 1.6 mm was registered (b); the increase in body height during this period was 18 cm. At the latest observation (25 years 2 months), no further increase in body height was found, but the infraocclusion had increased to 2.2 mm (c). The shift in the gingival margin and the marginal bone loss at the buccal aspect resulted in an unaesthetic appearance.

SD 0.99; Table 3), with additional bone loss of approximately 0.3 mm at the most recent examination, although with high individual variation (Figure 7). At three of the implants notable bone losses were registered. The soft tissue also became discoloured above these restorations (Figure 5), indicating loss of marginal bone support at the buccal aspect of the implant,



**Figure 4** Two patients 10 years after placement of implants in the upper lateral incisor regions. Note the unaesthetic appearance in the 25-year-old male with unilateral replacement of the right lateral (a), contrary to the satisfactory appearance in the 24-year-old female with bilateral replacement, due to symmetry (b). The infra-occlusion at the three implant-supported crowns was of the same degree (0.7 mm).

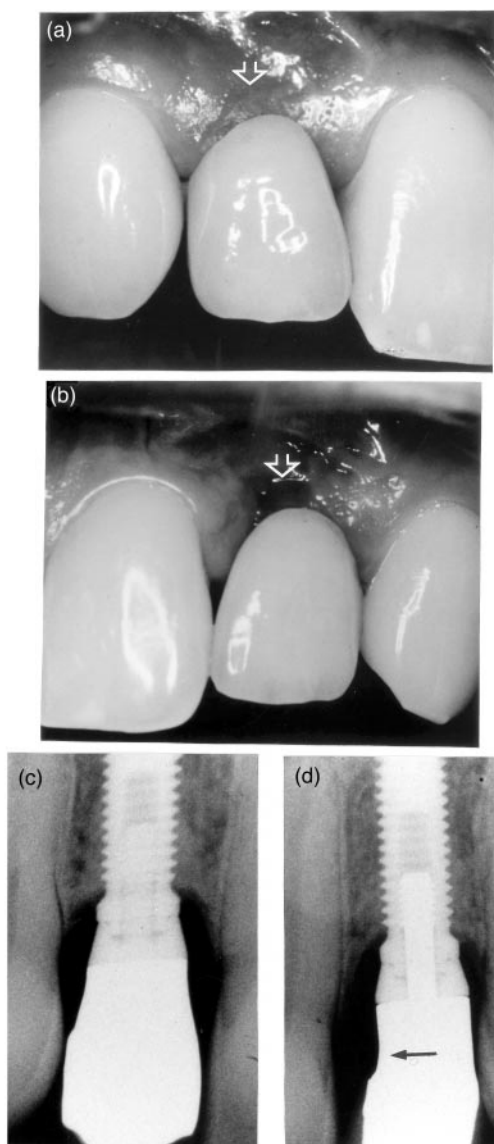
**Table 2** Longitudinal changes (mm) in infra-occlusion of the 17 single implants in the upper incisor region. Mean values with standard deviation within brackets.

1 year after CP	0.13 (0.14)
2 years after CP	0.29 (0.28)
3 years after CP	0.46 (0.38)
4 years after CP	0.59 (0.47)
6 years after CP	0.78 (0.50)
8 years after CP	0.95 (0.59)
10 years after CP	0.98 (0.62)

Range: 0.1–2.2 mm. CP = crown placement.

further verified by gingival retraction. Due to the unfavourable aesthetic appearance, the crowns had to be replaced on two of the laterals, which involved additional expense to the patients.

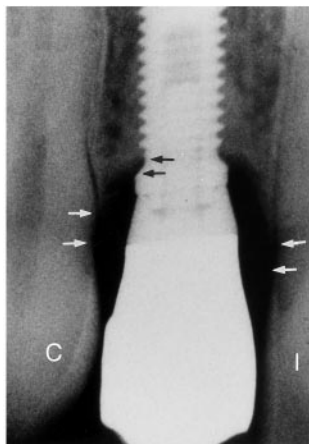
A reduction of the marginal bone level at the teeth adjacent to the implants was observed in



**Figure 5** Clinical photographs (a,b) and peri-apical radiographs (c,d) of the two upper lateral incisors in a 25-year-old woman, 10 years after placement of implant-supported crowns. Discoloured gingiva (a) and gingival retraction with bone loss (b, open arrows). Note the incorrect anatomy of the implant-supported crown (d, arrow).

some patients, all losses being related to the central incisors (Table 3). The largest change occurred during the interval between pre-operative examination and crown placement, with additional changes throughout the observation period. Altogether, a mean of 4.3 mm mesially





**Figure 6** Peri-apical radiograph showing the reference points used for analysing the marginal bone level changes at implants (vertical distance between a fixed reference point of the fixture and marginal bone level of the fixture) and at adjacent teeth (vertical distance between cemento-enamel junction and marginal bone level; marked with arrows).

and 2.2 mm distally to the incisor implant was registered, although with great individual variation (Figure 7). The data indicated that the shorter the distance between the implant and the adjoining tooth surfaces, the larger the reduction of marginal bone level.

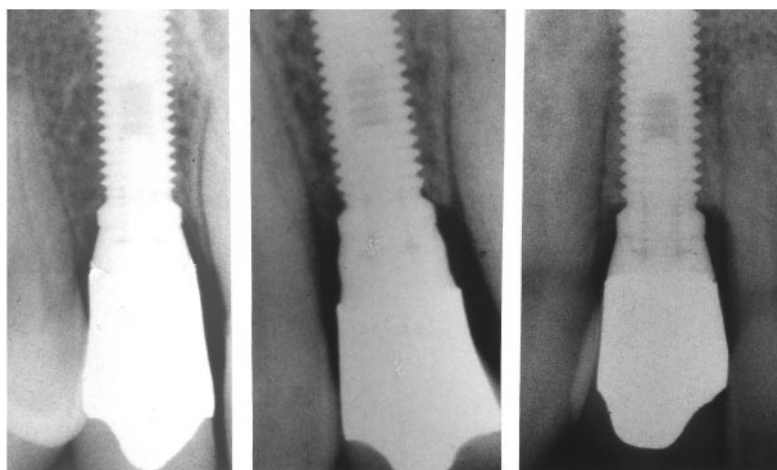
**Table 3** Marginal bone loss (mm) at implants in the upper lateral incisor area and bone level changes at tooth surfaces adjacent to the implants. Mean values with standard deviation within brackets.

	Implants	Central incisor	Canine
At CP	0.51 (0.99)	2.1 (1.6)	0.8 (1.0)
1 year after CP	0.59 (0.78)	2.8 (1.9)	1.4 (1.3)
3 years after CP	0.64 (0.56)	3.2 (2.3)	1.8 (1.5)
10 years after CP	0.75 (0.44)	4.3 (2.7)	2.2 (1.7)

CP = crown placement.

### *Single implants in canine regions*

In one 16-year-old girl, two implants had been inserted bilaterally in the upper arch, while in another girl (14 years of age) one implant was placed in the lower arch. In contrast to the crown-supported implants in the incisor region, none of these implants was in a measurable infraoccluded position at the most recent examination. The marginal bone loss observed at the implants was minimal (0.6 mm), but similar to the adjacent teeth (0.8 mm).



**Figure 7** Three representative peri-apical radiographs illustrating different degrees of marginal bone loss at implants in upper lateral areas and at adjacent tooth surfaces (minimal, medium and notable loss), 10 years after crown placement.

*Single implants in premolar regions*

In three of the patients (mean 15.4 years of age), nine implants had been inserted (all but two in the lower arch). At the 3-year observation, all implant-supported crowns showed a minor degree of infraocclusion (0.1–0.6 mm), related to the increase in body height during that period (1–4 cm). At the final control, however, all crowns were in occlusion, although in some cases a minor occlusal step between the implant-supported crown and its adjacent molar was noticed.

Two of the patients had persistent deciduous molars at the time of implant placement. In one of them (Figure 8) the mandibular infraoccluded deciduous molars on the right side were extracted one month before implant placement, whereas the left one with a permanent successor was maintained. No difference in occlusion between the two sides was observed at the most recent examination, except for a small step between the implant-supported crowns and their adjacent teeth.

In the other patient, who had all premolars congenitally missing (Figure 9), it was decided to retain the non-infraoccluded deciduous molars and replace the others with implants. At the latest observation (the patient now being 24 years of age) the retained deciduous molars were still in place and in function, as well as the implant-supported crowns. They will be replaced with implants after their spontaneous exfoliation.

In a 13-year-old girl with 12 congenitally missing teeth (Figure 10), orthodontic treatment was initiated to upright the second molars and align the dental arches. The bone volume in the upper right area was judged to be too thin to allow installation of implants, and a fixed prosthodontic construction (FPC) was suggested. For the same reason, implant placement was also judged to be contra-indicated in the lower left area. Instead, the left first premolar was orthodontically distalized one cusp-width, and an implant was then placed in the expanded area between this premolar and the canine. The latest examination (at the age of 28 years) showed excellent bone integration. The marginal bone loss at all the nine implants and at their adjacent

teeth was minimal, their mean being less than 0.5 mm, indicating very high bone integration.

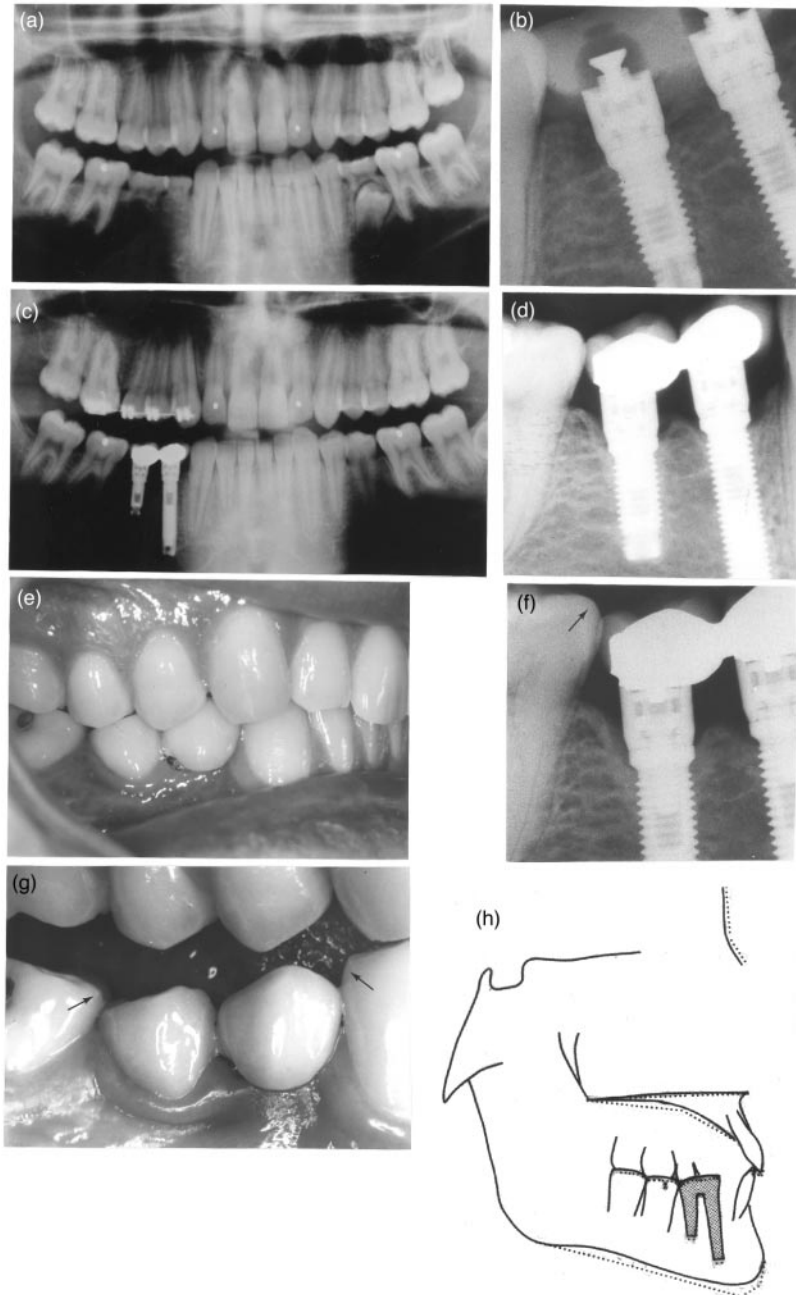
*Implants in combination with fixed prosthodontics in children with extensive aplasia*

In this group, 18 implants replaced two incisors, four canines, and four premolars in maxillae, and seven incisors and one canine in the mandibles as either single units or connected to FPCs. Two 15-year-old boys with advanced to extreme resorption in the lateral segments in both arches illustrate the treatment plan and follow-up result (Figures 11 and 12). The implants were installed as support for the FPC, which were placed 4–6 months after the surgical procedure. The prosthodontic constructions functioned well throughout the observation period and all the implants remained stable. Peri-apical radiographs showed some marginal bone loss during the first year in function (mean 0.6 mm), but no further measurable loss was registered during the following observations. In one boy (Figure 12), the increase in body height during the 10-year period was 6 cm, also verified by cephalometric superimpositioning as slight craniofacial growth changes. The implant-supported FPC remained stable in the vertically displaced mandible.

**Discussion**

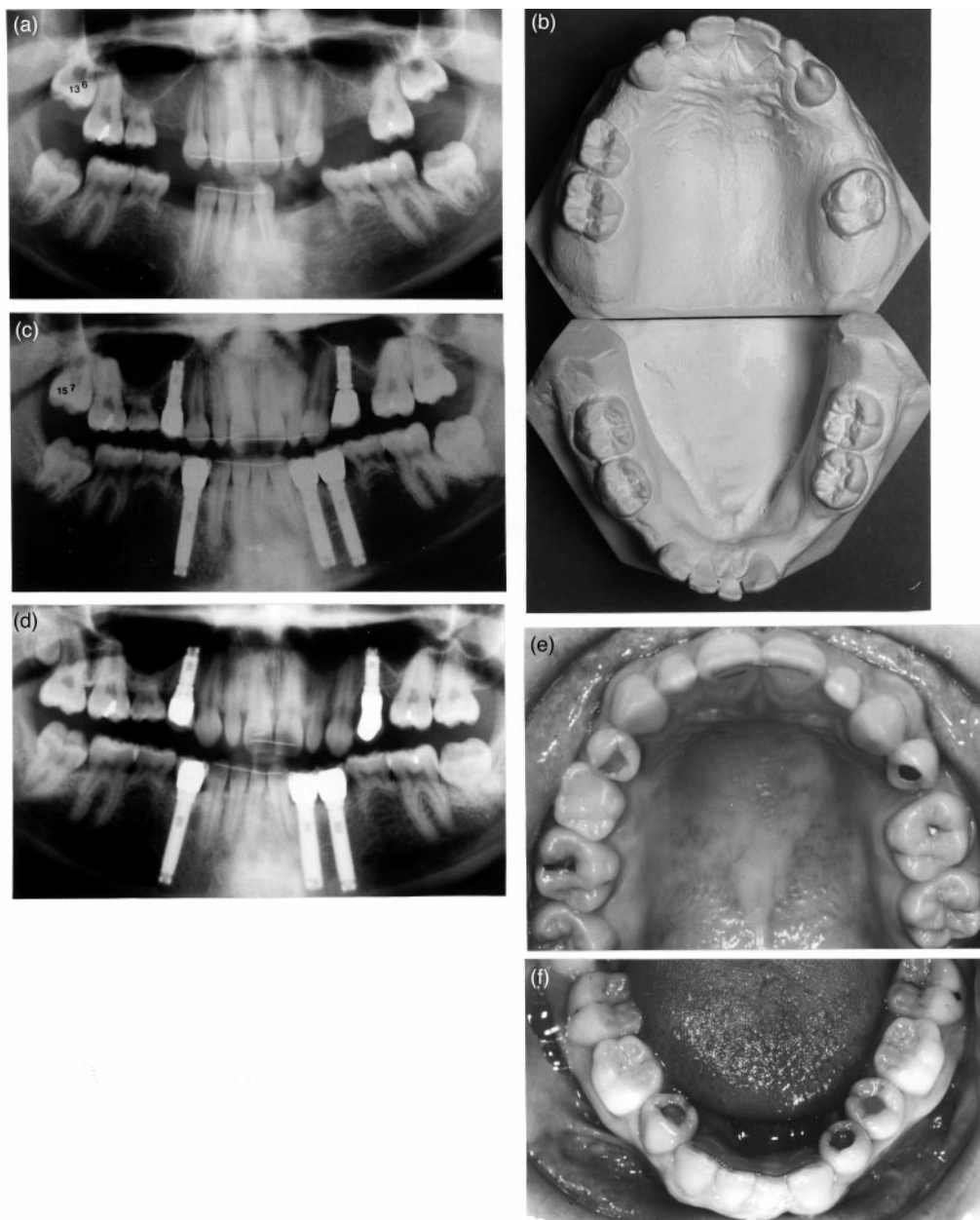
The present follow-up study has clearly shown that oral implants are a good treatment option for replacing missing teeth in adolescents, provided that the subject's dental and skeletal development is complete. However, it is of importance to realize that different problems are related to the premolar and incisor regions, which have to be considered in the total treatment planning. Thus, a careful analysis of the individual patient has to be performed by an inter-disciplinary team (orthodontist, surgeon, prosthodontist) to achieve the best possible aesthetic long-term result in individuals with missing incisors, and from a functional point of view in subjects with missing premolars or extensive hypodontia.

All implant-supported crowns in the premolar region were in good occlusion despite a minimal

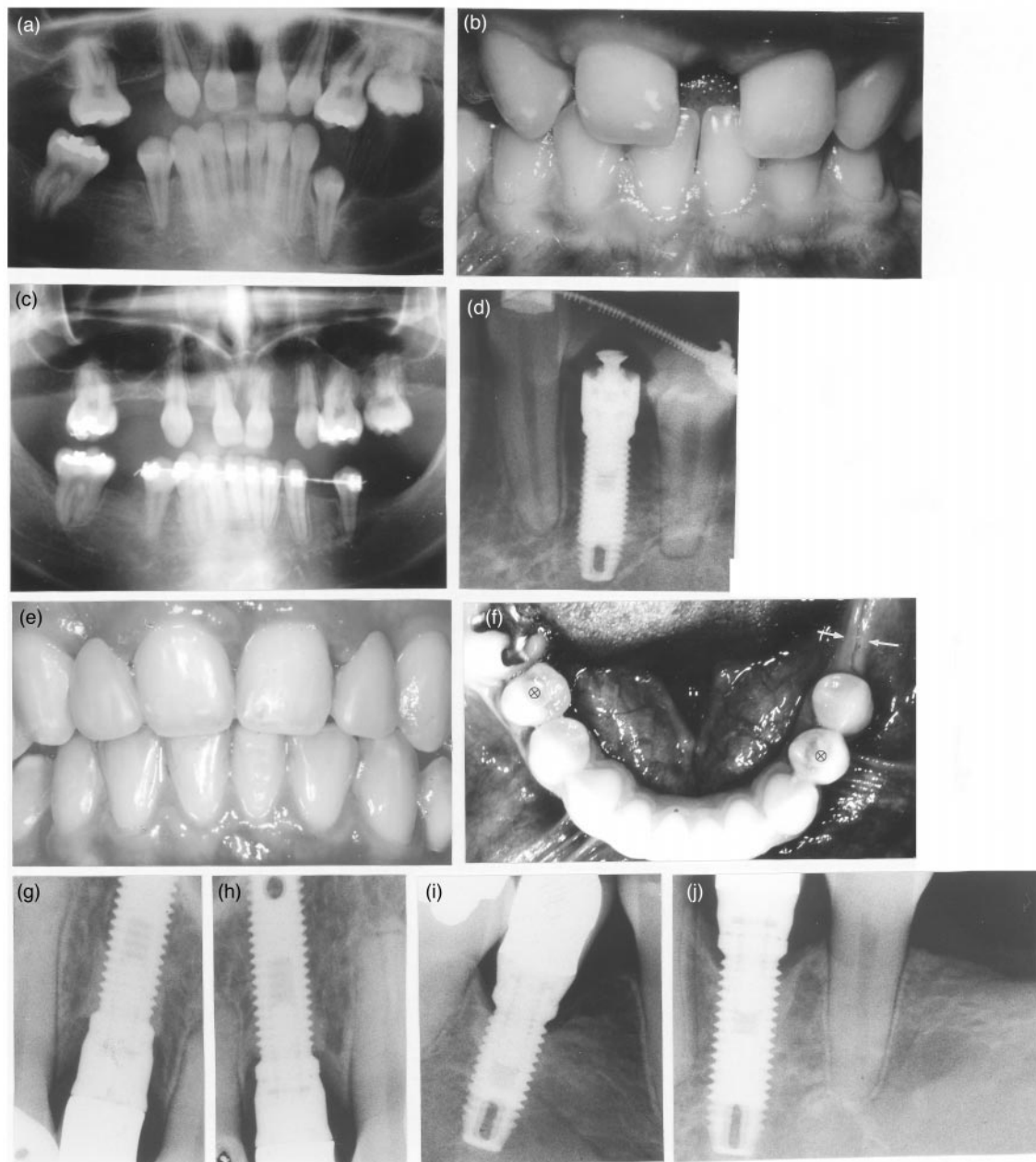


**Figure 8** A 13-year-old boy with congenitally missing premolars in the right lower arch (a). The deciduous molars are infraoccluded, even the second one on the left side. After spontaneous eruption of the permanent left successor, two implants were placed on the right side at the age of 14 years 6 months (skeletal age MP3-H; b). The right maxillary dentition was splinted between the time of extraction of the deciduous molars and placement of implant-supported crowns in good occlusion to avoid over-eruption (c,d). Clinical photograph (e) and peri-apical radiograph at the most recent examination (23 years 10 months) show good results, apart from a step between the implants and the first molar and canine, respectively (f,g, arrows). The increase in body height during the 10-year observation period was 3 cm. Superimposition of the cephalograms (from the first and last control) showed vertical growth of the mandible (h). The implant-supported crowns remained stable in the displaced mandible.





**Figure 9** A 13-year-old girl with all permanent premolars and two lower incisors congenitally missing (a,b). It was decided to retain the three non-infraoccluded deciduous molars and to replace the others with implants. At the age of 14 years 11 months (skeletal stage MP3-I), two implants were placed in the upper arch and three in the lower arch (c). Panoramic radiograph (d) and clinical photographs at the age of 24 years 5 months (e,f) showed good results, with the deciduous molars still *in situ*. The increase in body height during the whole observation period was 1.5 cm, and the superimposed cephalograms did not show any significant craniofacial growth.



**Figure 10** A 13-year-old girl with 12 congenitally missing teeth (a,b). In the maxilla, it was decided to align the dental arch and to close the median diastema to gain space for replacement of the laterals by implants. The bone volume in the upper right area was judged to be too thin to allow installation of an implant, and an FPC was planned. In the mandible, it was decided to align the dental arch and to place an implant in the right premolar region. On the left side, implant placement was contra-indicated due to the thin bone volume in the bucco-lingual direction. Instead, the left first premolar was moved distally one cusp-width (c), and an implant was installed in the created space (17 years 2 months, skeletal stage R-IJ; d). At the last observation (28 years old), a good result was registered (e,f), with excellent bone integration of all implants (g-j). Note the thin bucco-lingual bone volume in the lower left area (f, arrows), posterior to the distalized first premolar. The implant-supported crowns in the mandible are indicated by an asterisk.

step to the adjacent molar in a few subjects. This may be explained by a compensatory over-eruption of the premolar in the opposite arch during the time between insertion of the implant and placement of its crown. To avoid this risk, the teeth in the opposite jaw should be splinted until the implant-supported crown is in place. Another explanation for this step is that the implant-supported crown gradually came into an infraoccluded position due to continuous eruption of the adjacent molar, according to the findings of Iseri and Solow (1996). They registered continuous eruption of upper first molars in females, even after 16 years of age. Furthermore, Sarnäs and Solow (1980) found that the average amount of late continued eruption was of the same magnitude for incisors and molars (about 1 mm) in samples of males and females studied longitudinally from 21 to 26 years of age.

In some of the patients in the present investigation, both premolars were congenitally missing in the same quadrant with persistent deciduous molars. The life span of the deciduous molars is not known, but the long-term prognosis is generally assumed to be poor, especially in the upper arch. Thus, it is often difficult to decide whether they should be left or extracted. The decision regarding extraction/non-extraction in the present subjects was based on the results from the longitudinal studies of Kurol and Thilander (1984a,b), i.e. deciduous molars not being in infraocclusion were left *in situ*, while infraoccluded ones were extracted, due to the risk of progression of the infraocclusion and, hence, further loss of bone height.

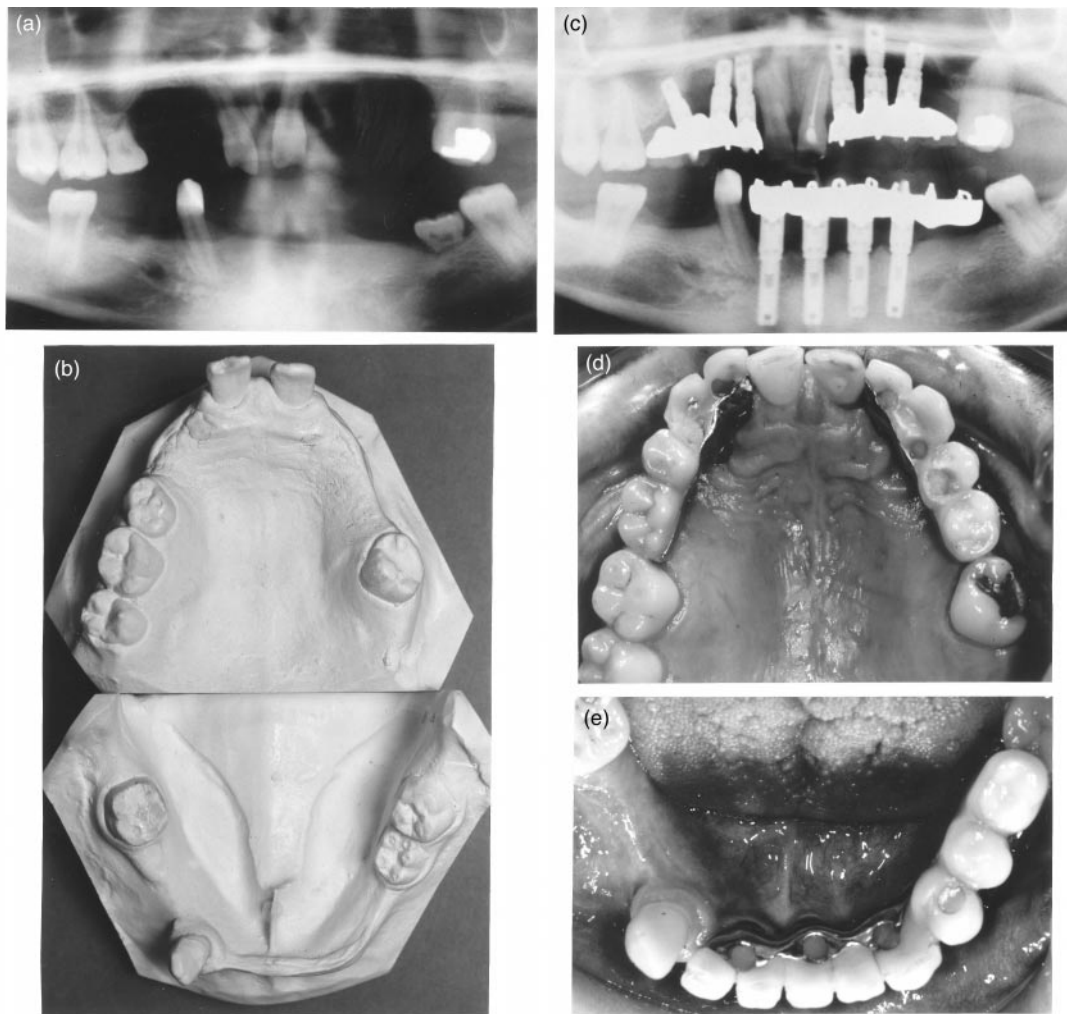
An implant in the lower premolar region needs sufficient space, not only in the mesio-distal, but above all in the bucco-lingual direction. Persistent infraoccluded deciduous molars should therefore be extracted shortly before placement of an implant to avoid an hour-glass-shaped alveolar bone, due to resorption in the bucco-lingual dimension, which may jeopardize implant placement. In such cases, an adjacent tooth can be orthodontically moved into this transformed area to rebuild the bone volume. Lindskog-Stokland *et al.* (1993) have shown that orthodontic tooth movements in the dog may

build up reduced alveolar bone height, a finding that has been verified in adults (Thilander, 1996). Such a procedure is also shown in one of the present patients (Figure 10), in whom a lower first premolar was orthodontically distalized one cusp-width. Whether this premolar could have been moved further distally can only be speculated upon. Of great interest, however, is the excellent bone integration of the implant, placed in the expanded area between the canine and the distalized premolar.

In most cases, oral implants in the upper incisor region resulted in a good aesthetic result. However, the continuous eruption of adjacent teeth, even after completed dental and skeletal development, may result in an infraoccluded implant-supported crown. During the last 6-year observation period with completed growth, the mean infraocclusion increased from 0.59 mm (SD 0.47) to 0.98 mm (SD 0.62; Table 2), i.e. by a mean of nearly 0.1 mm per year. These findings are in agreement with the results of Iseri and Solow (1996). Such continuous eruption changes, even of a minor degree, will cause an unaesthetic appearance in subjects with unilateral missing incisors, contrary to those with bilateral aplasia.

It is of interest to note that no or only a minor degree of infraocclusion was observed in patients with good inter-incisor stability, while missing anterior tooth contacts were associated with a more obvious degree of infraocclusion. Thus, inter-incisor stability has to be achieved before placement of osseo-integrated implants. It should also be remembered that tooth wear is a common occurrence, and that the prevalence and severity will increase with increasing age (Silness *et al.*, 1994). The pattern of incisor wear may thus counteract the continuous eruption.

The present follow-up results have clearly shown that the critical area for placing implants is that for the upper incisors, especially laterals. In the inter-disciplinary treatment procedure, the orthodontic treatment has to be completed before the placement of the implant in order to gain sufficient space, and upright and parallel the adjacent teeth, even in the apical area, due to the dimensions of the implant. Over-expansion is sometimes recommended, but may result in tipping of the roots with decreased distances

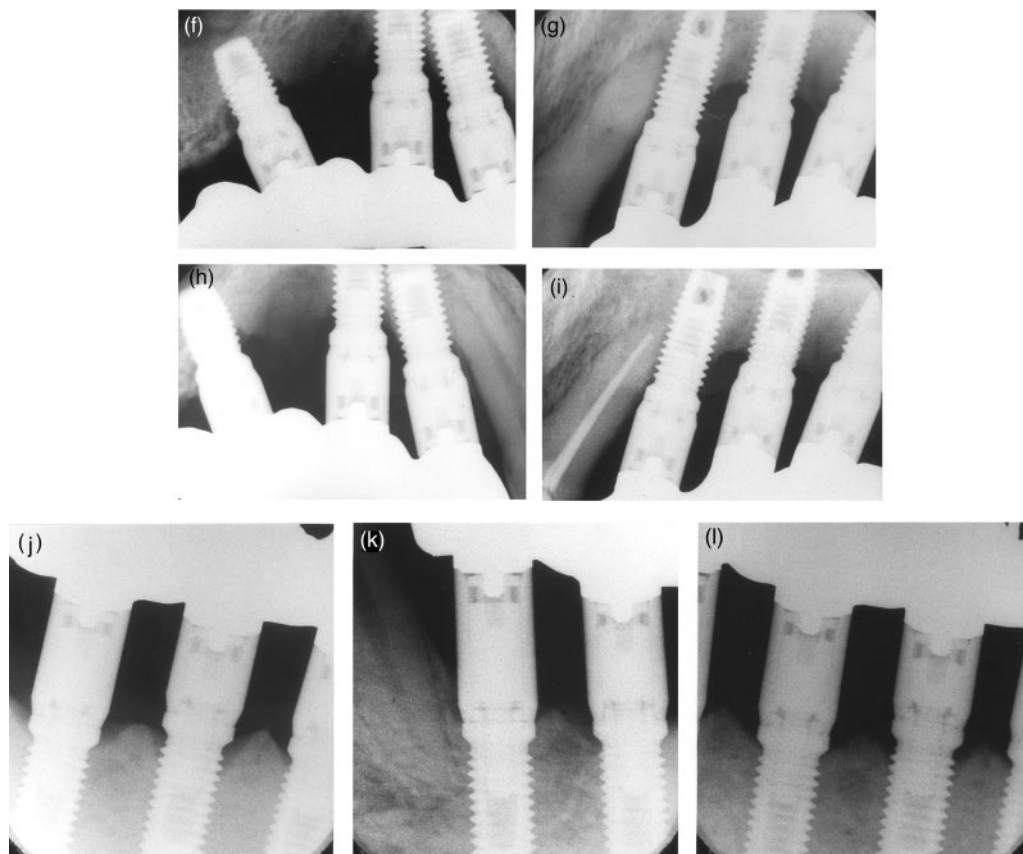


**Figure 11** A 15-year-old boy with only eight permanent teeth (a,b) was treated orthodontically to close the median diastema. The resorption in the lateral alveolar processes in the maxilla was judged to be extreme, but it was still decided to install three implants on each side as abutments for an implant-supported construction at the age of 16 years 9 months (skeletal stage R-II). In the lower arch, the prognosis for implants in the lateral segments was judged to be dubious due to advanced resorption. Instead, four implants were placed in the anterior segment, serving as abutments for an FPC, at the age of 17 years 2 months. The prosthodontic constructions have functioned well throughout the total observation period (c–e), and all the implants have been stable and without marginal bone loss, as illustrated by peri-apical radiographs from the start (f,g,j) and at the most recent examination (27 years 10 months; h,i,k,l). However, the left central incisor had to be endodontically treated four years after implant placement, due to trauma. The increase in body height between fixture placement and 10 years later was 1.5 cm. Superimpositioning of the cephalograms did not show any growth changes.

in the apical area. Another orthodontic problem is to avoid intrusion of the adjacent teeth, as later relapse may result in further infraocclusion of the implant-supported crown. The orthodontic treatment has to be completed with good

stability, followed by retention of the orthodontically moved teeth. Finally, it is important to stress that even small tooth movements after implant placement may cause complications, e.g. tipping of the central incisor may result





**Figure 11** Continued (f-l).

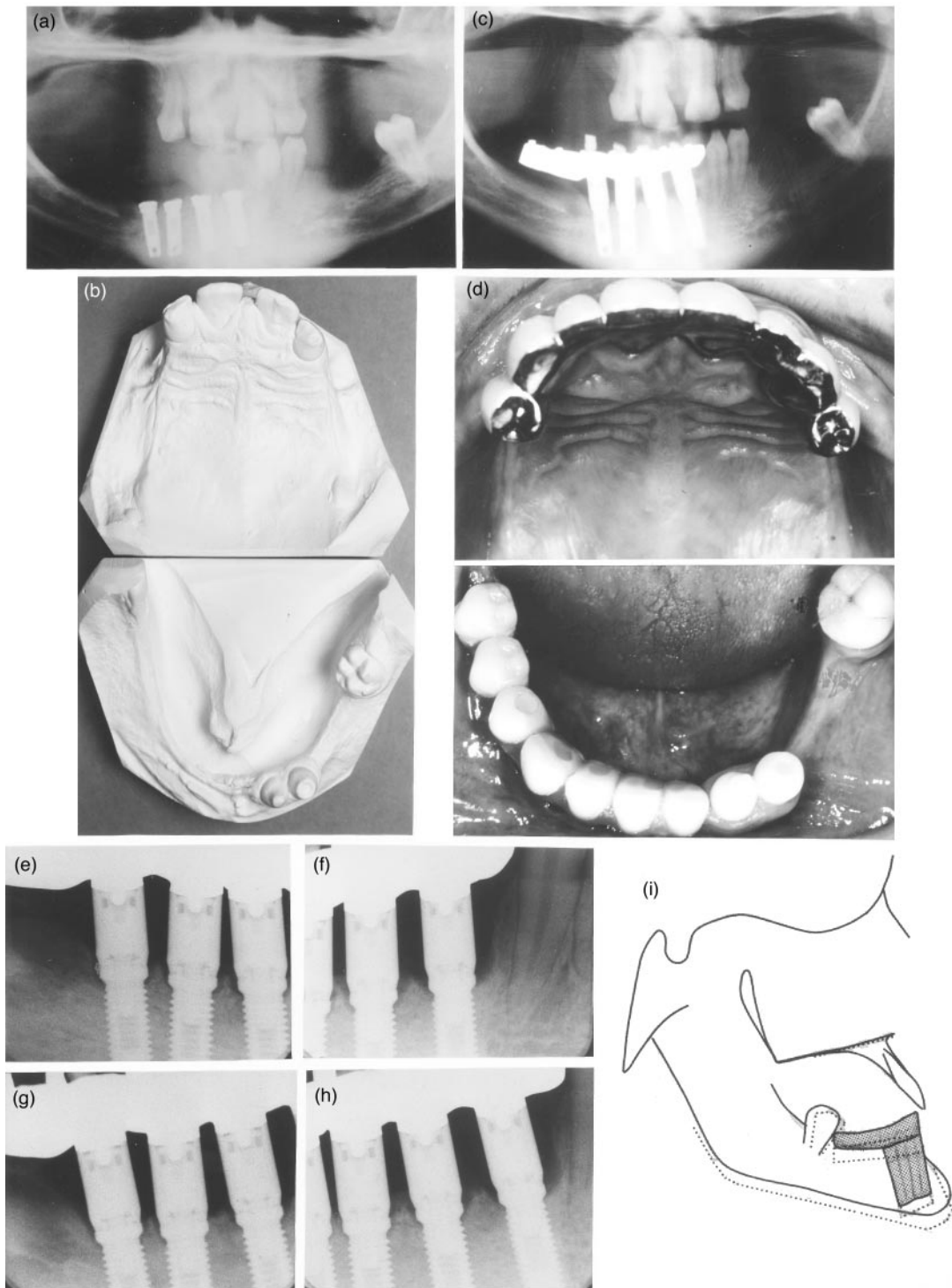
in tooth-implant contact with marginal bone loss.

The oral rehabilitation with FPC-supported implants in the three patients with extensive aplasia has clearly shown that such a technique can be used with good results in subjects with completed or almost completed craniofacial growth. In one of the subjects with an increase in body height of 6 cm during the observation period, the superimposed cephalograms showed a slight vertical craniofacial growth (Figure 12). The implants remained stable in the displaced mandible, which is in agreement with findings in the growing pig (Thilander *et al.*, 1992). In this case, the growth was mainly vertically directed. If, however, it had been associated with a mandibular rotation, it might have resulted in labial exposure of the implants due to bone

remodelling. It has to be stressed that these implants were placed in totally edentulous or partially edentulous jaws, and the result is in agreement with earlier published follow-up results (Brånemark *et al.*, 1977; Adell *et al.*, 1990; Zarb and Schmitt, 1993a,b). The use of endosseous implants in a few young individuals with ectodermal dysplasia has also been reported (Bergendal *et al.*, 1991; Cronin and Oesterle, 1994), but knowledge of the long-term outcome of such treatment in young children is, as yet, limited.

The results from the present follow-up study clearly indicate that there are physiological occlusal changes, not only from adolescence into young adulthood, but also into old age. The occlusion is a result of a developmental process in which the main events are facial growth, dental





development, and function. These genetically and environmentally conditioned processes show a great deal of individual variation throughout life. Thus, the occlusion has to be regarded as a dynamic, rather than a static, interrelationship between facial structures, a factor of importance in the discussion of the biological basis for relapse after orthodontic treatment (Thilander, 2000).

The peri-apical radiographs showed loss of marginal bone up to 1 mm round all implants throughout the observation period. Most of this bone loss occurred during the first year of function, i.e. between abutment connection and the 1-year follow-up. Only minor differences were registered after that time, except for some implants replacing upper lateral incisors. This is in agreement with general experiences of the Brånemark System® (Jemt *et al.*, 1990; Esposito *et al.*, 1993). The reason for the main loss during the first year of function is not well understood, but may to some extent relate to the design of the implant head. During loading of endosseous implants, stresses will be conveyed through the implant to the bone interface. 'Physiological' loading by chewing will have a positive influence on bone remodelling, a theory in agreement with the findings of Strid (1985), who reported an increase in peri-implant bone density during the first two years after placement. These findings may explain the excellent bone tissue response after prolonged loading of all the FPC-supported implants in the patients with extensive aplasia.

At the teeth adjacent to the implants, a reduction of alveolar height was observed, but of varying degrees in different implant areas, i.e. minimal in the premolar region, but more obvious in the upper incisor region. The latter area showed that the mean cemento-alveolar

junction (CEJ) to alveolar crest distance at crown placement was 2.1 mm mesial and 0.8 mm distal to the implant, with a gradual deterioration throughout the observation period. It should be noted that large individual variations were recorded, which is in agreement with the results of Källestål and Matsson (1989). Based on their findings in normal non-diseased tooth areas in adolescents, it is reasonable to consider that a bone loss is present if the distance between the CEJ and alveolar bone crest exceeds 2 mm. Thus, reduced bone support was present at some of the lateral incisors adjacent to the implant in the present follow-up study, which is in agreement with findings of Avivi-Arber and Zarb (1996). In a study of implant-supported single-tooth replacement, they also found that some implants did not meet the proposed bone level criteria, and they concluded that no success criteria exist for natural teeth adjacent to implants.

The data from the present study clearly indicate that the shorter the distance between the implant and the adjacent teeth, the larger the reduction of marginal bone level, which is especially relevant for the upper lateral incisors, and in agreement with findings of Esposito *et al.* (1993) and Andersson *et al.* (1995). Thus, it is important for the orthodontist to gain sufficient space for the implant before it is placed. It is also worth noting that the buccal bone plate in the lateral incisor area is often very thin after orthodontic treatment. In a few cases, discoloured soft tissue buccally to the implant-supported crown was also observed, indicating ongoing bone resorption, which even resulted in gingival retraction and/or a denuded implant due to vigorous tooth brushing. A factor that may contribute to this complication is an

**Figure 12** A 15-year-old boy with only seven permanent teeth (b) and extreme resorption of the alveolar process in both arches. Contra-indications for implants existed in the upper arch due to insufficient bone volume. Orthodontic treatment, to close the median diastema and distalize the canines for placement of a FPC, was refused by the patient. In the lower arch, four implants were installed in the anterior region at the age of 15 years 5 months (skeletal stage MP3-I; a). Due to the thin alveolar bone height in the lateral segments and the location of the mental foramina, implant placement was judged to be contra-indicated in the posterior regions. A FPC with posterior extension on the right side was installed 5 months later (c). Peri-apical radiographs on this occasion (e,f) indicated good integration. At the 10-year control (24 years 10 months) all implants showed good stability with no marginal bone loss (g,h). The patient was now also interested in orthodontic treatment in the upper anterior region, as discussed earlier, a therapy that was followed by conventional fixed bridge work. The patient was happy with the final clinical result (d). The increase in body height during the observation period was 6 cm, which could also be verified by the downward mandibular growth pattern (i). The implant-supported construction was stable in the displaced jaw, while the permanent molar had erupted during this period.

unsatisfactory anatomy of the implant-supported crown. Hence, it is of importance that implants are placed with sufficient alveolar bone support all around the site, i.e. even buccally, to avoid such a negative effect.

## Conclusions

There are advantages with the implant treatment modality, e.g. implants replacing premolars from functional aspects and implants replacing incisors for aesthetic reasons. Disadvantages, however, may be related to the incisor region, especially for the upper lateral incisors, due to the slight continuous eruption of teeth and craniofacial changes post-adolescence. Finally, periodontal problems may arise, with marginal bone loss around the adjacent teeth and bone loss buccally to the implants.

It is thus important that a careful analysis of the individual patient is performed before implant placement to achieve the best possible long-term result, aesthetically in subjects with missing incisors, and functionally in those with missing premolars or extensive aplasia. The following factors should be considered:

1. A fixed chronological age is no guide for implant placement. A dental stage, indicating fully erupted permanent teeth and skeletal maturation, completed or almost completed, is not sufficient to avoid infraocclusion of the implant-supported crown, due to slight continuous eruption of the adjacent teeth post-adolescence, especially in the upper incisor region.
2. The aim of the orthodontic treatment performed before placement of the implant is to gain sufficient space in the implant area, and upright and parallel the adjacent teeth, even in the apical area, using non-intrusive tooth movements.
  - The shorter the distance between the implant and the adjacent teeth, the larger the reduction of the marginal bone level, which is most relevant for the upper lateral incisors.
  - In the premolar region, sufficient space is needed, not only in the mesio-distal, but

above all in the bucco-lingual direction. An infraoccluded lower deciduous molar should be extracted shortly before placement of the implant to avoid reduction of the bucco-lingual alveolar bone volume.

3. Oral rehabilitation with FPC-supported implants seems to be a good alternative in adolescents with extensive aplasia, provided that craniofacial growth is complete or almost complete.

## Address for correspondence

Professor Birgit Thilander  
Department of Orthodontics  
Faculty of Odontology  
Box 450  
SE 405 30 Göteborg  
Sweden

## References

- Adell R, Lekholm U, Brånemark P-I 1985 Surgical procedures. In: Brånemark P-I, Zarb G A, Albrektsson T (eds) *Tissue-integrated prostheses: osseointegration in clinical dentistry*. Quintessence, Chicago, pp. 211–232
- Adell R, Eriksson B, Lekholm U, Brånemark P-I, Jemt T 1990 A long-term follow-up study of osseointegrated implants in the treatment of the totally edentulous jaw. *International Journal of Oral Maxillofacial Implants* 5: 347–359
- Ainamo J, Talari A 1976 Eruptive movements of teeth in human adults. In: Poole D F G, Stack M V (eds) *The eruption and occlusion of teeth*. Butterworths, London, pp. 97–107
- Andersson B, Ödman P, Lindvall A-M 1995 Single-tooth restorations on osseointegrated implants: results and experiences from a prospective study after 2–3 years. *International Journal of Oral and Maxillofacial Implants* 10: 702–711
- Avivi-Arber L, Zarb G A 1996 Clinical effectiveness of implant-supported single-tooth replacement. *International Journal of Oral and Maxillofacial Implants* 11: 311–321
- Behrents R G 1985 Growth in the aging craniofacial skeleton, Monograph No. 17, Craniofacial Growth Series. Center for Human Growth and Development, University of Michigan, Ann Arbor, pp. 1–145
- Bergendahl T, Eckerdahl O, Hallonsten A-L, Koch G, Kurol J, Kvint S 1991 Osseointegrated implants in the oral habilitation of a boy with ectodermal dysplasia: a case report. *International Dental Journal* 41: 149–156
- Björk A, Skieller V 1983 Normal and abnormal growth of the mandible. A synthesis of longitudinal cephalometric

- implant studies over a period of 25 years. *European Journal of Orthodontics* 5: 1–46
- Brånemark P-I, Hansson B O, Adell R, Breine U, Lindström J, Hallén O, Öhman A 1977 Osseointegrated implants in the treatment of the edentulous jaw. Experiences from a 10-year period. *Almqvist and Wiksell International, Stockholm*
- Cronin R J, Oesterle L J 1994 Mandibular implants in the growing patient. *International Journal of Oral Maxillofacial Implants* 9: 55–62
- Esposito M A B, Ekstubbé A, Gröndahl K 1993 Radiological evaluation of marginal bone loss at tooth surfaces facing single Brånemark implants. *Clinical Oral Implants Research* 4: 151–157
- Forsberg C-M, Eliasson S, Westergren H 1991 Face height and tooth eruption in adults. A 20-year follow-up investigation. *European Journal of Orthodontics* 13: 249–254
- Hägg U, Taranger J 1980 Skeletal stages of the hand and wrist as indicators of the pubertal growth spurt. *Acta Odontologica Scandinavica* 38: 187–200
- Henry P, Laney W, Jemt T, Harris D, Krogh P, Polizzi G, Zarb G, Herrman I 1996 Osseointegrated implants for single-tooth replacement: a prospective 5-year multicenter study. *International Journal of Oral Maxillofacial Implants* 11: 450–455
- Iseri H, Solow B 1996 Continued eruption of maxillary incisors and first molars in girls from 9 to 25 years, studied by the implant method. *European Journal of Orthodontics* 18: 245–256
- Jemt T, Lekholm U, Gröndahl K 1990 A 3-year follow-up study of early single implant restorations *ad modum* Brånemark. *International Journal of Periodontics and Restorative Dentistry* 17: 327–333
- Källestål C, Matsson L 1989 Criteria for assessment of interproximal bone loss on bite-wing radiographs in adolescents. *Journal of Clinical Periodontology* 16: 300–304
- Kurol J, Thilander B 1984a Infra-occlusion of primary molars and the effect on occlusal development: a longitudinal study. *European Journal of Orthodontics* 6: 277–293
- Kurol J, Thilander B 1984b Infra-occlusion of primary molars with aplasia of the permanent successor: a longitudinal study. *Angle Orthodontist* 54: 283–294
- Lekholm U, Gunne J, Henry P, Higuchi K, Lindén U, Bergström C, van Steenberghe D 1999 Survival of the Brånemark implants in partially edentulous jaws. A 10-year prospective multicenter study. *International Journal of Oral Maxillofacial Implants* 14: 639–645
- Lindskog-Stokland B, Wennström J, Nyman S, Thilander B 1993 Orthodontic tooth movement into edentulous areas with reduced bone height. An experimental study in the dog. *European Journal of Orthodontics* 15: 89–96
- Ödman J, Gröndahl K, Lekholm U, Thilander B 1991 The effect of osseointegrated implants on the dento-alveolar development. A clinical and radiographic study in growing pigs. *European Journal of Orthodontics* 13: 279–286
- Sarnäs K V, Solow B 1980 Early adult changes in the skeletal and soft-tissue profile. *European Journal of Orthodontics* 2: 1–12
- Sennerby L, Ödman J, Lekholm U, Thilander B 1993 Tissue reactions towards titanium implants inserted in growing jaws. A histological study in the pig. *Clinical Oral Implants Research* 4: 65–75
- Silness J, Berge M, Johannessen G 1994 Prevalence, pattern and severity of incisal wear in dental students. *Acta Odontologica Scandinavica* 52: 178–181
- Strid K-G 1985 Radiographic results. In: Brånemark P-I, Zarb G A, Albrektsson T (eds) *Tissue-integrated prostheses. Osseointegration in clinical dentistry*. Quintessence Publication Co, Chicago, pp. 187–198
- Tallgren A, Solow B 1991 Age differences in adult dentoalveolar heights. *European Journal of Orthodontics* 13: 149–156
- Thilander B 1996 Infra-bony pockets and reduced alveolar bone height in relation to orthodontic therapy. *Seminars in Orthodontics* 2: 55–61
- Thilander B 2000 Biological basis for orthodontic relapse. *Seminars in Orthodontics* 6: 195–205
- Thilander B, Ödman J, Gröndahl K, Lekholm U 1992 Aspects on osseointegrated implants inserted in growing jaws. A biometric and radiographic study in the young pig. *European Journal of Orthodontics* 14: 99–109
- Thilander B, Ödman J, Gröndahl K, Friberg B 1994 Osseointegrated implants in adolescents. An alternative in replacing missing teeth? *European Journal of Orthodontics* 16: 84–95
- Thilander B, Ödman J, Jemt T 1999 Single implants in the upper incisor region and their relationship to the adjacent teeth. An 8-year follow-up study. *Clinical Oral Implants Research* 10: 346–355
- Zarb G A, Jansson T 1985 Prosthodontic procedures. In: Brånemark P-I, Zarb G A, Albrektsson T (eds) *Tissue-integrated prostheses: osseointegration in clinical dentistry*. Quintessence, Chicago, pp. 241–282
- Zarb G A, Schmitt A 1993a The longitudinal clinical effectiveness of osseointegrated dental implants in anterior partially edentulous patients. *International Journal of Prosthodontics* 6: 180–188
- Zarb G A, Schmitt A 1993b The longitudinal clinical effectiveness of osseointegrated dental implants in posterior partially edentulous patients. *International Journal of Prosthodontics* 6: 189–196





Copyright of European Journal of Orthodontics is the property of Oxford University Press / UK and its content may not be copied or emailed to multiple sites or posted to a listserv without the copyright holder's express written permission. However, users may print, download, or email articles for individual use.